

Design & Development of Novel Hybrid Set of Rules for Detection and type of Malignant or Non-Malignant Tumor in Human Brain based on SVM Using Artificial Intelligence Classifier.

Anwaar Ahmad Wani¹ Lone Faisal² Madiha zahoor³ Juneed Iqbal⁴

¹ Assistant Professor (C), Higher Education Department, Government of J&K Srinagar, UT- J&K, India

² Assistant Professor, Department of Electrical Engineering, Mewar University Rajasthan India,

³ Assistant Professor (C), Higher Education Department, Government of J&K Srinagar, UT- J&K, India

⁴ Assistant Professor (C), Higher Education Department, Government of J&K Srinagar, UT- J&K, India

Article Info

Page Number: 10253 - 10276

Publication Issue:

Vol 71 No. 4 (2022)

Abstract

Thousands of lives are lost across globe due to the malignant and non-malignant tumor. The detection of brain tumor is very crucial as brain tumor is a life threatening disease and proper treatment and efficient diagnosis is very beneficial. This paper proposes exhaustive computerized crossover set of rules for detection and type of malignant and non-malignant tumor. MATLAB center capacity and photo handling tool stash are used for the proposed method. The proposed framework recognizes and segments a tumor, processes significant boundaries that incorporates tumor length and region. The paper also proposes a contraption that finds elements of mind experiencing tumor and shows the related manifestations and anticipation connection. The proposed framework with the aid of numerous techniques divided for the division for skull recognition and vertical ways for tumor identification, rule based absolutely fluffy sound judgment for mind part influenced realities uncover and morphology for tumor division. Then research also detect the tumor and localization, tumor segmentation and area computation and as an outcome we will be able to recognize the area or location of the tumor

Keywords: Brain Tumor, Noise Filtration, Segmentation, MATLAB

Article History

Article Received: 15 September 2022

Revised: 25 October 2022

Accepted: 14 November 2022

Publication: 21 December 2022

1. Introduction:

The primary organ of the human nervous system is the brain. It approaches, integrates, and coordinates facts acquired from the sensory organs and makes choices about instructions which might be sent to other frame parts. The brain is contained and guarded by using the skull of the top. Human mind is made up of cerebrum, brainstem and cerebellum. Brain controls most body activities. It is divided into two cerebral hemispheres. An outer layer of grey count number called cerebral cortex covers the white count number nucleons'. The cortex is also divided into parts: neocortex and allocortex. The neocortex consists of six neural layers, even as allocortex has three or four.

Each hemisphere is partitioned into 4 lobes: the frontal, temporal, parietal and occipital. The primary process of frontal lobe is to allow us to assume. Making judgements, taking movement, fixing problems, making plans, self-control, and reasoning are a few functions of frontal lobe. The parietal lobe relates with the sense of touch. The occipital lobe controls imaginative and prescient and recognition. The cortical area is blended with each lobe having specific feature. The form and function of the left and proper hemispheres are approximately comparable.

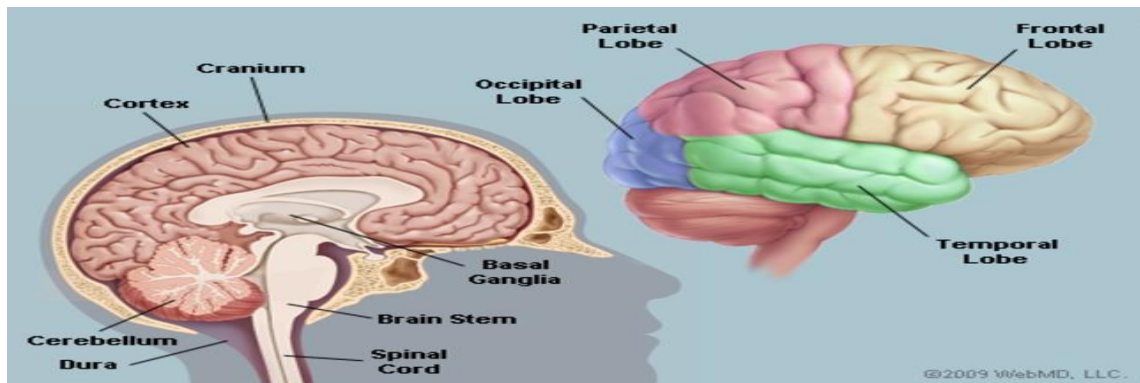


Figure 1: Human Brain Anatomy (HBA)

1.1 Brain Tumor: Our frame is made of billions of cells. Normally those cells multiply and restore in a controlled way and do no longer purpose troubles. If this method is interrupted, cells can begin to grow uncontrollably, a cellular clot, known as a tumor, develops. So, a mind tumor is a lump inside the mind. This occurs while mind cells divide and develop out of manage. Malignant (cancerous) and benign tumors are the two most important varieties of tumors. Cancerous tumors may be subdivided into number one tumors that begin within the brain and secondary tumors that unfold to different places, known as mind metastases. All forms of brain tumors can cause signs and symptoms that rely on a part of the brain. These signs and symptoms can include complications, seizures, blurred vision, vomiting, and mental changes. The headache is the worst traditional in the morning and disappears with vomiting. Other signs may be problem in walking, speakme or feeling. With innovative illness it may come to unconsciousness.

Generally, the analysis is made via a clinical exam together with computed tomography (CT) or magnetic resonance imaging (MRI). The end result is frequently showed through biopsy. According to the consequences, the tumors are categorized into distinct degrees of severity. The treatment might also encompass a mixture of surgery, radiotherapy and Chemotherapy. Medication may be used to lessen swelling around the tumor. Some tumors grow steadily, requiring best surveillance and likely no additional intervention. Treatments that use a person's immune system are studied. The consequences range extensively according to the sort of tumor and its occurrence at the time of diagnosis. Glioblastoma frequently indicates very poor consequences, at the same time as meningioma generally gives true effects. The common five-yr survival fee for all mind tumors inside the United States is 33%.

1.2 Classification of Brain Tumor: A brain tumor known as an intracranial tumor is an unusual tissue mass wherein cells develop and reproduce uncontrollably, apparently unrestricted with the

aid of the mechanisms controlling normal cells. More than 150 exceptional brain tumors were documented, however the most important brain tumors are referred to as "primary" and "metastatic." Primary brain tumors include tumors which are directly derived from brain tissue or brain regions. Primary tumors are categorized as glial (which includes glial cells) or non-glial (located on brain systems or brain structures, consisting of nerves, blood vessels, glands) and benign or malignant. Brain tumors encompass tumors that originate in other components of the frame, along with the breast or lungs, and usually migrate thru the blood to the brain.

Metastatic tumors are taken into consideration to be cancers and malignant tumors. Brain tumors affect nearly a quarter of most cancer sufferers, or an estimated a hundred and fifty,000 people in keeping with yr. Up to 40% of lung cancer patients develop a wide range of brain tumors. In the past, sufferers recognized with these tumors had very poor outcomes and survived simplest for a few weeks. In addition to revolutionary surgical and radiotherapy strategies, extra superior diagnostic gear have helped enhance survival prices for many years; they're additionally allowed to enhance the first-rate of existence of patients after diagnosis.

1.3 Types of Benign Brain Tumor:

- Chordoma is a benign, slow-growing tumor this is maximum normal among people elderly 50 to 60. Their most common locations are the base of the skull and the decrease part of the spine. Although these tumors are benign, they'll invade adjoining bones and exert strain on close by nerve tissue. These are uncommon tumors that account for simplest 0.2% of all primary brain tumors.
- Craniopharyngioma is usually a benign tumor, but due to the fact it's far positioned near important systems deep inside the brain, it's miles tough to dispose of. They generally come from part of the pituitary gland (regulating the shape of many hormones inside the frame), so nearly all patients need some hormone replacement therapy.
- Ganglioblastoma, gangliomas, and anaplastic gliomas are rare tumors, along with tumor nerve cells, which include quite differentiated tumor nerve cells that occur normally in teens.
- Glomus jugular vein tumors are normally benign, normally placed simply below the bottom of the skull, on the pinnacle of the jugular vein. They are the maximum common shape of glomus tumor. However, in standard, glomus tumors account for simplest zero.6% of head and neck tumors.
- Meningioma is the maximum common benign intracranial tumor. They account for 10% to fifteen% of all brain tumors, although a small percentage are malignant. These tumors are derived from the membranous structures around the meninges, meninges and spinal cord.
- Pineal cell tumors are typically benign lesions due to pineal cells, mainly in adults. They are typically properly described, non-invasive, homogeneous and slowly growing.
- Pituitary adenomas are the most common intracranial tumors after glioma, meningioma and schwannoma. The significant majority of pituitary adenomas are benign and develop pretty slowly. Even malignant pituitary tumors rarely spread to different elements of the frame. Adenomas are by

way of far the maximum not unusual pituitary sickness. They frequently affect people in their 30s or 40s, even though they may be additionally identified in children. Most of those tumors may be successfully handled.

- Schwannomas are common benign brain tumors in adults. They arise alongside nerves that encompass cells that commonly form the "electrical insulation" for the nerve cells. Schwannomas regularly displace the relaxation of the regular nerve in place of infecting it. Acoustic neuromas are the most commonplace schwannomas emanating from the eighth cranial nerve or the vestibular cochlear nerve, which migrates from the mind to the ear. Although those Tumors are benign, they can purpose extreme complications or even death in the event that they develop and positioned strain on the nerves and subsequently on the brain. Other elements are the spine and seldom nerves that attain to the limbs.

1.4 Types of Malignant Brain Tumor:

- The maximum commonplace shape of person brain tumors is glioma, which money owed for 78% of malignant brain tumors. They come from the helping cells of the mind, so-referred to as glial cells. These cells are subdivided into astrocytes, ependymal cells and oligodendrocytes (or oligonucleotides).
- Glial mobile tumors consist of the subsequent:
- Astrocytoma is the most not unusual glioma, accounting for about half of of the number one tumors of the brain and spinal twine. Astrocytomas originate from astrocytic glial cells referred to as astrocytes, which might be part of the brain's helping tissues. They can occur in many components of the mind, but are most common inside the mind. Astrocytomas can be developed by using human beings of all ages, however they're greater not unusual in adults, especially center-aged men. Astrocytomas in the brain matrix are extra common in youngsters or teenagers and are a chief cause of mind tumors in children. In youngsters, most of these tumors are considered to be low-grade and excessive-adult.
- Ependymoma is a tumor transformation from the ventricular compartment cells of the ventricular machine, accounting for 2% to a few% of all mind tumors. Most are without a doubt described, but some are not.
- Glioblastoma multiforme (GBM) is the most aggressive glioma. These tumors have a tendency to develop hastily, spread to different tissues, and have a negative diagnosis. They can be composed of different styles of cells, which include astrocytes and oligodendrocytes. GBM is more commonplace in human beings aged 50-70, with men being greater not unusual than women.
- The medulloblastoma commonly occurs in the cerebellum and is most common place in children. They are excessive-grade tumors however generally reply to radiation and chemotherapy.
- Oligodendrogliomas come from cells that make up the myelin, which is a clue to the brain.

1.5 DIAGNOSTICS TECHNIQUES USED FOR HUMAN BRAIN:

Diagnostic tests and strategies are important tools that help doctors affirm or rule out a neurological disease or different scientific condition. A century ago, the only way to make a positive prognosis of many neurological issues was to behavior autopsies after the affected person's death. But many years of primary studies on the characteristics of the sickness, the improvement of techniques that allow scientists to see inside the brain and monitor the activity of the nervous system when it happens, have given medical doctors effective equipment and correct diagnosis of the disease and take a look at the satisfactory of a particular treatment can be work. Perhaps the maximum considerable modifications in diagnostic imaging during the last twenty years are enhancements inside the spatial decision (size, depth and clarity) of anatomical pics and a discount inside the time required to ship alerts to and capture information from the region to be imaged receive. These advances permit physicians to concurrently see the shape of the brain and modifications in mind pastime as they arise. Scientists retain to improve strategies that supply sharper anatomical pictures and more specific purposeful data.

A wide variety of tests and processes may be endorsed by using physician if a suspension of mind tumor takes place, such as:

A neurological examination: A neurological exam may additionally include, amongst different matters, checking your vision, hearing, stability, coordination, electricity and reflexes. If one finds out difficulty in one or more regions, it could be indication about the a part of mind that would be suffering from a brain tumor.

Imaging exams: In medical imaging, many techniques and methods are used to create snap shots of various elements of man or women frame which might be used for diagnose and remedy purposes. Magnetic resonance imaging (MRI) is commonly used to diagnose genuine area of mind tumors. Functional MRI, perfusion MRI and magnetic resonance spectroscopy are a few specialized MRI additives which can help physicians to discover the exact vicinity of tumor and plan treatment.

Many different kinds of imaging exams are recommended, inclusive of automatic tomography (CT). Positron emission tomography (PET) and so forth. Can be used for brain imaging, however they may be typically no longer as beneficial for creating photographs of mind cancer as for different types of most cancers.

1.6 IMAGE PROCESSING IN MEDICAL APPLICATIONS

Biomedical Imaging:

Biomedical imaging makes a speciality of imaging for diagnostic and therapeutic functions. The snapshots of vivo body structure and physiological procedures may be acquired via advanced sensors and laptop era. Biomedical imaging strategies use both x-rays (CT scans), sound (ultrasound), magnetometers (MRI), radioactive prescription drugs (nuclear remedy: SPECT or PET) or mild (endoscopy, OCT) to evaluate the present day state of a organ or tissue The affected person may be monitored through the years over time to evaluate diagnosis and treatment.

Molecular optical imaging techniques represent a new discipline of research that may be used to visualize human cells and molecules without the need for biopsy or mobile transplantation. Using contrast or imaging elements that bind to precise molecules, disorder approaches, such as most cancers, may be monitored earlier than their effects seem on the general pathology stage.

Optical harmonic tomography (OCT) is a new form of computerized tomography used in research that makes pics of mild that propagates and diffuses through the body. The strength of ultrasound is used together with small bubbles. Small bubbles may be injected directly into a specific vicinity and then burst with the aid of ultrasound to emit local contrast retailers for imaging and chemotherapy to treat cancer and air to help dissolve strokes, genes, or drugs that can effortlessly penetrate cell membranes that weaken ultrasound.

New imaging technologies convey new methods of looking on the human body, assisting to lessen the want for more invasive diagnostic and therapeutic procedures.

Biomedical Image Processing:

Biomedical photo processing is conceptually much like treating biomedical indicators in multiple dimensions. It includes analysis, enhancement and presentation of pics taken via X-rays, ultrasound, magnetic resonance imaging, nuclear medicine and optical imaging techniques.

Image reconstruction and modeling strategies allow the instant processing of 2D indicators to create 3D snap shots. When the original CT scanner become invented in 1972, it actually took hours to get one slice of picture information and more than 24 hours to reconstruct that information in one photo. Today, this acquisition and reconstruction takes place in much less than 2D.

Instead of just performing an X-ray scan on a lightbox, the photograph processing software program enables to automatically perceive and analyze what may not be visible to the human eye. Computerized algorithms can offer a temporal and spatial evaluation to locate styles and traits that seek advice from tumors and different illnesses.

Depending at the imaging approach and analysis being taken into consideration, picture processing and analysis can be used to determine the diameter, length, and recognition of the tumor or organ

2. Literature Review:

The brain tumor could be detected by using pretreatment, that is step one on this and by means of using indirect and diagonal anti-photograph masks that receive pretreatment. After the cranium disguise the adipose tissue and other undesirable info get smoothing. The formerly processed photograph is segmented the usage of K-Mean segmentation and item tagging the usage of HOG, a clean-to-use HOG with extraction function. So the texture and coloration characteristic is extracted here within the machine that is used to discover the location that pastimes you and the SVM tool is used for sample mapping and pattern matching. Also use to research neural community. Image processing has become a totally critical task in today's international. Today image processing packages may be installed in some of areas which includes medical, far off sensing, electronics and

so on. If we attention on clinical programs, image segmentation is broadly used for diagnostic reason. In this paper, a machine is proposed that may be used to divide MR snap shots to discover and identify a brain tumor. The tumor place and its type of tumor are discovered. The future scope of mind tumor detection and department is if we get a three-dimensional image of the mind with a tumor, we can also find out dimensions in addition to determine the tumor kind and also the tumor degree.

Image **processing** plays a essential function in trendy world. It has an critical application in biomedicine. The proposed gadget for tumor diagnosis become advanced from mind MRI photographs. This method makes the prognosis in many tiers. In pre-remedy filtering is finished on mind MR snap shots. In the photograph segmentation segment, the K-suggest grouping approach is used to divide the MR photograph. After the tissue capabilities are extracted from the gray MR photograph the usage of the GLCM method, these extracted features are given as inputs into the synthetic neural community to categories the MR photograph into a normal and peculiar (diffused) photograph. [2]

This technique ambitions to stumble on brain tumor from CT / MRI of brain images. The detected aspect is then fragmented using photo processing algorithms The results are offered in tables, one for CT and the alternative for MRI. From the numerical outcomes obtained we provide an explanation for that atypical kingdom values are usually excessive. [3]

By using a GUI-based application, a whole new lot higher outcomes than traditional tumor detection strategies can be get, is validated proper here. Using GUI-based software program application permits converting parameters without rewriting the software program software and permits for fast and efficient detection of tumors. The effects are really extra correct and quicker. [4]

The final aspect that can be drawn from this research: Elastix and Camino is a aspect tool in scientific and image processing. Studies say , a survey paper changed into final by means of reviewing 15 gear. This paper reviews present day medical image processing gear and recommends using numerous scientific photograph processing gear in scientific image analysis. The variety includes handiest medical imaging system. Each clinical photo processing (MIP) device has its private obstacles. [5]

MR photo is said as a tough hassle in medical image processing aspect . In widespread, it can be measured as the usage of traditional and direct picture processing strategies. Due to the trends of MR photographs, improvement of the basic automatic algorithms is hard. There is extensive variant amongst patients within the sign intensity of the equal tissue kind due to the impact of partial length and latent noise and a large variety of imaging parameters, which affect the severity of the tissue.. MATLAB simulation goes is carried out on specific mind photographs and is detected the use of the OTSU method for image department and maximum green global threshold. The discovery of mind tumors is a terrific aspect for doctors [6]

P. Nagabushanam, et.al shows an improved model thing is proposed to divide the mind tumor into an MR image. The word edges because of the proposed method have tons much much less faux

Edges and feature closed borders. Thus, brain tumors extracted from the approach are higher than tumors extracted the usage of element detection. Talking in phrases of three requirements, the proposed method have become placed to be superior in comparison to conventional techniques. In the future, the closed contour set of guidelines may be improved to growth the region of the location and reduce the thickness of the boundary traces of the regions. [7]

The image processing technique using MATLAB that identify the fault presents on the fabrics. For this image processing technique first image is taken, Noise Filtering, Histogram and Thresholding techniques are applied on the image and the output is get. First Input color fabric fault image to the Matlab in image processing system is done, then Color image to gray image conversion is done, then Noise removal and filtering from the image is done, Then Binary image conversion from the noise removed output is done, then Histogram output is obtain, then Thresholding technique is applied.[8]

Eric Olmedo and MansorMohd Noor. Jebat et al., 2005). Reflexively Eric Olmedo et al (2012) state that The point to point technique affect a transformation to each pixel of image concurrently , This method used CUDA(Compute Unified Device Architecture), as parallel programming tool on a GPU(Graphics Process Unit) to take advantage of all available cores. The basic results is that CUDA will gave better results in the most used filters[9].

3. METHODOLOGY OF BRAIN TUMOR DETECTION

In this block diagram ,firstlyinput MRI picture then adaptive noise filtration process is performed at the photograph. Then subsequent system is skull detection & centre orientation. After this, tumor is detected the usage of Bhattacharya rating vertical- horizontal minimum most location then next technique is tumor segmentation then tumor region, aspect of brain, affected lobes display and symptoms & diagnosis display additionally

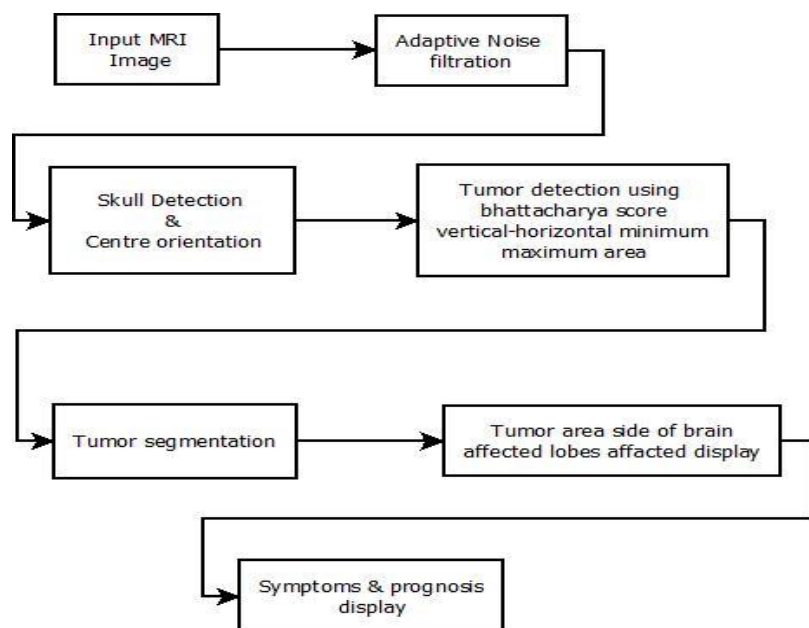


Fig. 3.1. System Block diagram

This particular aspect defines about the various methodologies we have carried over to find and get the desired results on the basis of the following terms.

The first consideration is on the basis that we will first take the input image and work on the particular image as and when we need to identify and segment and extract the basic consideration. so the first task is to input the original image. We need to run main that contains all the coding that we have done in matlab.

a. INPUT THE MRI IMAGES:

Firstly we will take the image will be browsed The input images are being browsed and taken into account for the first case and it is being defined . Level Set segmentation Loading an image A set of whole head MRI images was taken in the coronal plane are generated. This section explains with one of the MRI slices of how the level set segmentation procedure described, can be applied to segment out just the brain from a whole head MRI. A MRI image of the brain which was chosen and loaded into the system.

b. ADAPTIVE NOISE FILTARTION:

Adaptive filters are commonly used in image processing to enhance or restore data by removing noise without significantly blurring the structures in the image.. However, a large part of the literature concerns one-dimensional (1D) signals. Such methods are not directly applicable to image processing and there are no straightforward ways to extend 1D techniques to higher dimensions primarily because there is no unique ordering of data points in dimensions higher than one. Since higher-dimensional medical image data are not uncommon (2D images, 3D volumes, 4D time-volumes), we have chosen to focus this chapter on adaptive filtering techniques that can be generalized to multidimensional signals.

c. SKULL DETECTION & CENTER ORIENTATION:

Using the contour aspect we have made a skull detection and ROI and the centre orientation part being defined. To isolate the brain from non-brain tissues using a fully automatic method may be affected by the presence of radio frequency non-homogeneity of MR images (MRI), regional anatomy, MR sequences, and the subjects of the study. In order to automate the brain tumor (Glioblastoma) detection, we proposed a novel approach of skull stripping for axial slices derived from MRI. Then, the brain tumor was detected using multi-level threshold segmentation based on histogram analysis. Skull-stripping method, was applied by adaptive morphological operations approach. This is considered an empirical threshold by calculation of the area of brain tissue, iteratively. It was employed on the registration of non-contrast T1-weighted (T1-WI) and its corresponding fluid attenuated inversion recovery sequence.

d. TUMOR DETECTION:

In this we have validated the symptoms in the notepad we have just checked it through google and in this we have checked what is the size and the location of the tumor.The area being affected due to

tumor is defined in the last aspect. Automation of Landmark Selection, Registration and Optimization Image warping is used to register mMRM and histological sections to blockface imaging. The image warping technique is developed based on thin-plate splines with point-landmark optimization. The technique developed in this project is an extension of our landmark optimization method, in which contours are manually drawn on the anatomical features on the MRI and histological sections, and corresponding landmarks are extracted from the contours and optimized according their distance and local curvature. In this project, we fully automate the semiautomatic method with the introduction of normalized mutual information (NMI). Implemented Technique The source image (MRI slice) will be first aligned with the target (blockface image) images using affine transformation. The edge maps (gradients) of the images will be calculated. One point landmark is placed on the centroid, and four landmarks are placed on the brain boundaries detected on 66 the edge maps. The four boundary landmarks are distributed every 90° from the centroid of each slice after affine transformation. The landmarks on the source image are then relaxed to move in a region A. Nonlinear transformation will be performed on the source image and the NMI of the source and target will be calculated.

4. PROPOSED ALGORITHM FOR BRAIN TUMOR DETECTION

The Main purpose of the proposed work is to carry out the basic functionality of MATLAB with the functions and then using the function to input the images, providing the noise filtration then detecting the skull and its orientation and finally segmenting the brain tumor. With this basis the researchers will be able to recognize the very basic aspects that are really crucial in a way to find out the tumor and its segmentation and even the prescription will be defined as well.

Image Processing Toolbox presents a comprehensive set of reference-wellknown algorithms and workflow apps for image processing, evaluation, visualization, and set of rules improvement. We can perform picture segmentation, image enhancement, noise discount, geometric differences, photograph registration, and 3D photograph processing. With the picture processing toolbox apps, we are able to automate not unusual photo processing workflows. We can section photo information interactively, examine photograph registration techniques, and batch-process big data sets. Visualization features and apps allow us to browse pics, 3-d volumes, and films; modify contrast; create histograms; and manipulate areas of interest (ROIs).

4.1 In this flow chart, it shows the algorithm for the basic scenario

- Start
- Begin the code
- clear all display & input variable.
- The main displays menu.
- Enter in variable.
- It will be checked that is $y=1$ if it is actual then input MRI photograph and speak to primary.
- Then test subsequent condition this is $y=2$ if it's far genuine then filter out adaptive noise then name main.

- check subsequent situation this is $y=3$ if it is authentic then skull detection & centre orientation then call important.
- check subsequent situation that is $y=4$ if it's miles proper then tumor detection then name important.
- After this test next situation that is $y=5$ if it's miles proper then next system is tumor segmentation. T
- Then name important and after this
- check subsequent condition that is $y== 'r'$ or $y== 'q'$ then
- clean& display exit mode then set of rules can be stop.

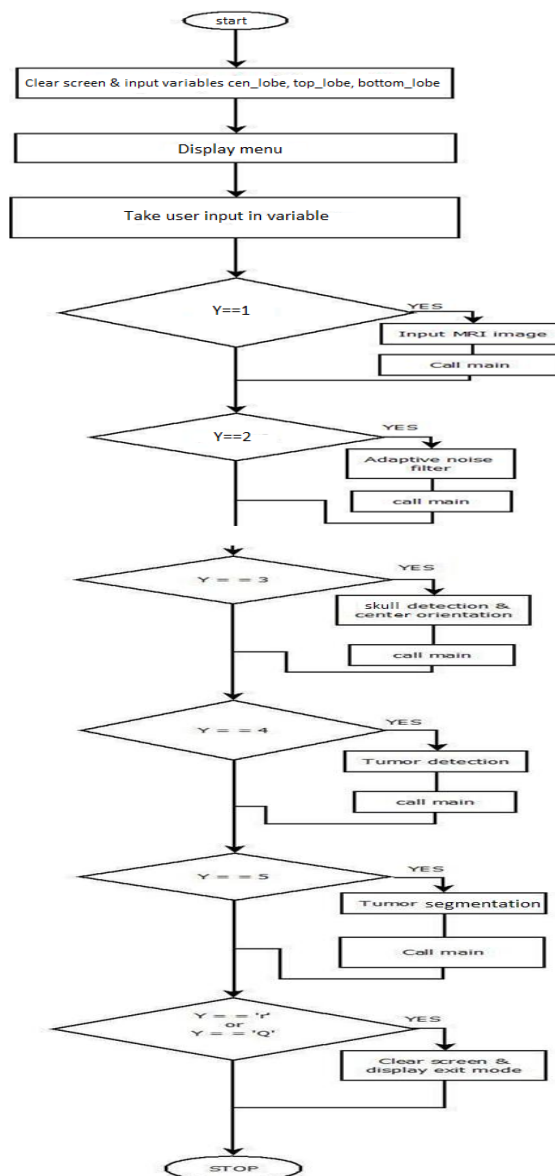
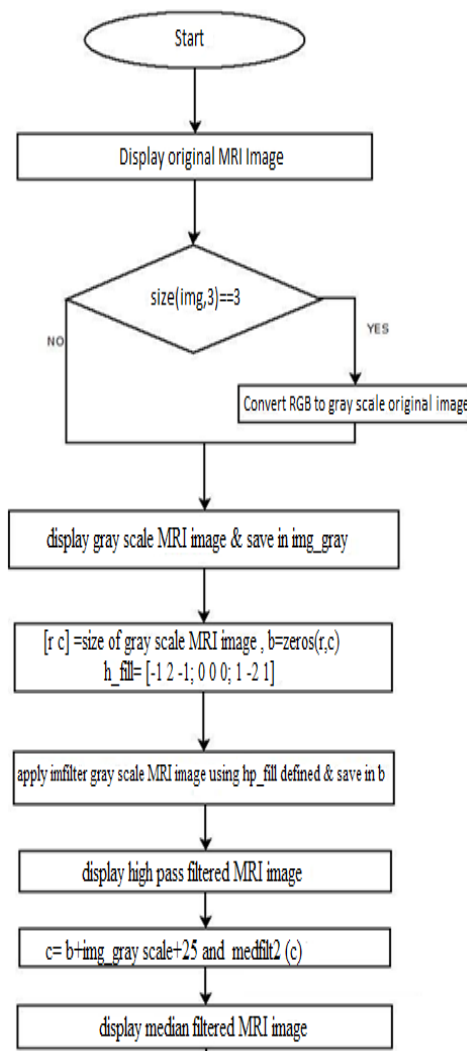


Figure 4.1 Main Menu Flow Chart

4.2 ADAPTIVE NOISE FILTERING ALGORITHM ALONG WITH FLOW CHART

- Begin the main code then display original MRI image
- Test a circumstance test size (img,three)==3 if genuine convert RGB to gray scale original image
- Display grey scale MRI image & keep in img_gray.
- The values [r c] =size of gray scale MRI photo.
- This observeimfilter gray scale MRI image the usage of hp_fill defined & store in b.
- This show excessive bypass filtered MRI image.
- Then $c = b + \text{img_gray scale} + 25$ and medfilt2 (c) then show median filtered MRI photo.
- Then compute gray threshold of median filtered the usage of $T = \text{graythresh}(c)$ and $\text{bw} = \text{Im2bw}(c, T + \text{zero}.30)$.
- This show binarized MRI photograph.
- Then compute watershed using watershed(bw) and shops in bw5 and watershed MRI image will be displayed then set of rules will be stop.



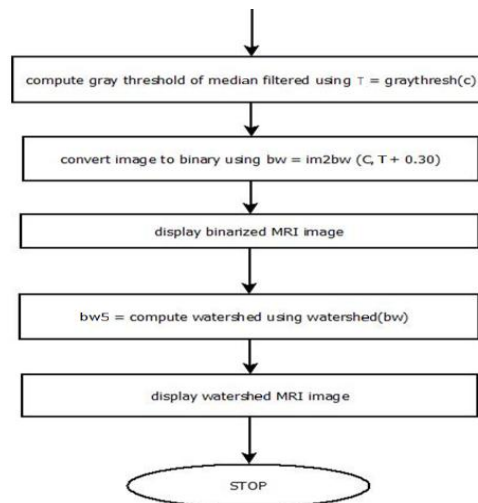


Fig. 4.2 . Adaptive Noise Filtering Flow Chart

4.3 SKULL DETECTION & ORIENTATION ALGORITHM ALONG WITH FLOW CHART

- Start the main code by taking input MRI image in I.
- Then see the values $I(1:end,1)=0$, $I(1:end,end)=0$, $I(1,1:end)=0$, $I(end,1:end)=0$ then fill image holes using $J = \text{imfill}(I, \text{'holes'})$
- Convert I to from gray scale to binary using $K = \text{im2bw}(J/\max(J(:)), 0.3 * \text{graythresh}(J/\max(J(:))))$ then label all connected components using $[L,N] = \text{bwlabel}(K)$.
- Now, initialize $\max a = 0$ & $\max i = 0$ for $i = 1$ to N for a statement $a = \text{sum}(\text{sum}(L == i))$. Then convert L to floating points & find maxima label $L = \text{double}(L == \max i)$.
- Create new figure window and show L then compute labeled region using $\text{STATS} = \text{regionprops}(L, \text{'all'})$. STATS.Centroid get using $x0 = \text{round}(\text{STATS.Centroid}(1))$, $y0 = \text{round}(\text{STATS.Centroid}(2))$.
- Now, compute $[h,w] = \text{size}(I)$. $\text{temp} = I(y0 - \min(y0, h - y0) + 1 : y0 + \min(y0, h - y0), x0 - \min(x0, w - x0) + 1 : x0 + \min(x0, w - x0))$, clear I and $I = \text{temp}$ and clear temp.
- $\text{Temp} = L(y0 - \min(y0, h - y0) + 1 : y0 + \min(y0, h - y0), x0 - \min(x0, w - x0) + 1 : x0 + \min(x0, w - x0))$, $L = \text{temp}$ and clear temp.
- Now, compute orientation using STATS.
- Orientation and check a condition that is STATS.
- $\text{Orientation} < 0$ if is true $M = \text{imrotate}(L, -90 - \text{STATS.Orientation})$ and $I = \text{imrotate}(I, -90 - \text{STATS.Orientation})$.
- if it is not true $M = \text{imrotate}(L, 90 - \text{STATS.Orientation})$ and $I = \text{imrotate}(I, 90 - \text{STATS.Orientation})$.
- Then algorithm will be stopped.

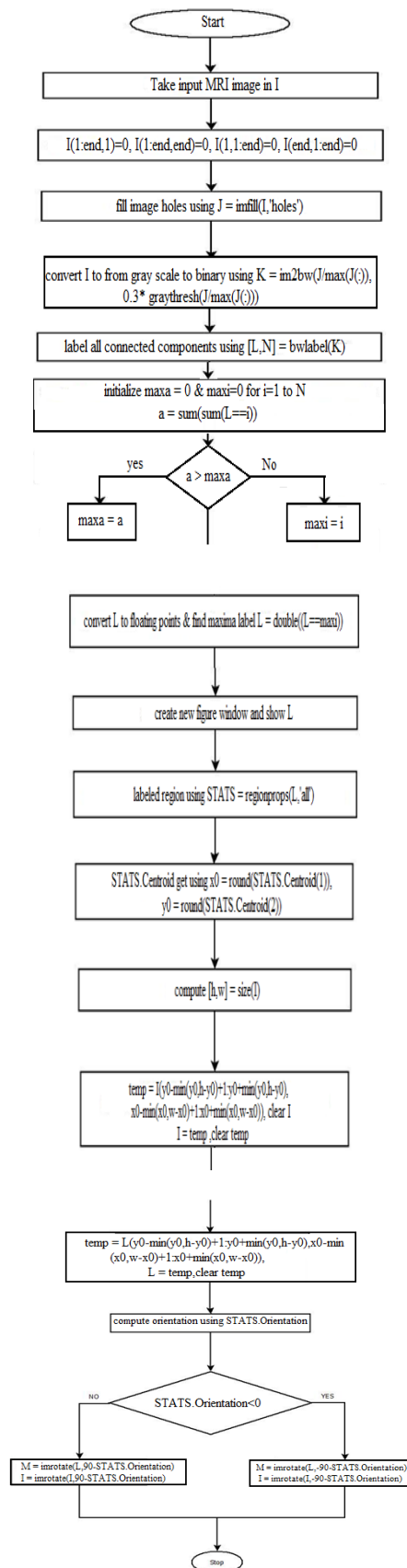


Fig. 4.3. SKULL DETECTION & ORIENTATION

4.4 TUMOR DETECTION & LOCALIZATION ALGORITHM

- .Start & Create skull segmented image in I
- Skull boundary $Im = I(:, midx: - 1: 1)$,
- Ref I = I (:, midx : end), RefIMask = m(: , midx : end) starti = round[STATS.BoundingBox(2)], endi = round[STATS.BoundingBox(2) + STATS.BoundingBox(4)] and Initialize fact = 16
- Compute Bhattacharya score from top down as BC_diff_Td = score(Im,RefI,ImMusk,RefIMusk,starti,endi,fact)
- Create new figure window plot (starti:endi, BC_diff_TD) titled 'score plot for vertical direction'.
- Now, define vert_scale = 30 & compute largest decreasing segment as [topy1, downy1] = find_largest_decreasing_segment(BC_diff_TD, vert_scale)
- Compute topy = topy(1) & downy = downy(1) and hold on.
- Plot(top y+ starti- 1, BC_diff_TD(topy), 'r.' , downy + starti - 1, BC_diff_TD(downy), 'm.', 'markerSize', 10)
- Compute topy = topy + starti -1 & downy = downy + starti-1 then hold off & create new figure window.
- Then Im = (Im(topy:downy,:))' ImMask = (ImMask(topy:downy,:))' RefI = (RefI(topy:downy,:))' RefIMask = (RefIMask(topy: downy,:))' & then startj =1; endj = floor(min(STATS.BoundingBox(1)+ STATS.BoundingBox(3) - midx+1, midx-STATS.BoundingBox.Box(1)+1)) then compute bhattacharya score from left to right BC_diff_LR = score (Im,RefI, ImMask,RefImask,startj, endj,fact).
- Initialize horz_scale=30 & compute[leftx1,rightx1] = find_largest_devresing_segment(BC_diff_LRhorz_scale) then compute leftx = leftx1(1), rightx =rightx1(1), leftx2 = leftx1(1), rightx2 = rightx1(1)
- Compute leftx=leftx+midx+startj-1, rightx=rightx+midx+startj-1, m_right=mean2(I(topy:downy, leftx:rightx)), m_left = mean2 (I(topy: downy), 2 * midx-rightx:2 * midx -leftx).
- Now initialize isleft = 0 and check if m_left>m_right then leftx1 = 2*midx – rightx, rightx1 = 2*midx-leftx, leftx=leftx1, rightx = rightx1, isleft = 1 and it ends.
- Now check if isleft = 1 then a condition start that is if it is false then plot(midx+startj : midx+endj, BC_diff_LR, 'r'), hold on, plot(leftx,BC_diff_LR(leftx2)), 'c.', rightx, BC_diff_LR(rightx2, 'y').
- If it is true then plot(midx-endj:midx-startj,-BC_diff_LR(end : -1 :1),'r'), hold on, plot(right X, -BC_diff_LR(leftx2), 'y.', leftx,-BC_diff_LR(rightx2), 'c')
- Create new figure window & display skull_image, with title 'Tumor Detection', hold on then plot([leftx:rightx], [topy, topy], 'r'), plot([leftx:rightx], [downy, downy], 'g'), plot([leftx, leftx],[topy downy], 'c'); plot([rightx, rightx],[topy downy], 'y') then cenX = (leftx + rightx) / 2 cenY = (topy + downy) / 2, hold on, plot(cenX,cenY,'+', 'color','r'); drawnow; hold on, plot([midx:midx],[1 h], 'linewidth', 2); drawnow; hold on, plot([1 w],[0.40*h 0.40*h], 'linewidth', 2); drawnow; hold on,

```
plot([1 w],[0.45*h 0.45*h], 'linewidth', 2); drawnow;hold on, plot([1 w],[0.55*h 0.55*h],
'linewidth', 2); drawnow;hold on, plot([1 w],[0.85*h 0.85*h], 'linewidth', 2); drawnow.
```

- A condition will be checked if $cenX < (midx - (w/8))$ then display ('Left Brain').
- Next condition will be checked that is $cenX > (midx - (w/8)) \ \& \ cenX \leq (midx + (w/8))$ then display ('Center Brain').
- Next condition is $cenX > (midx + (w/8))$ then display ('Right Brain') then next condition is $cenY > 0 \ \& \ cenY \leq (0.40 * h)$ then display 'Frontal Lobe', $cen_lobe=1$, and print Frontal.txt.
- Next condition is if $cenY > (0.40 * h) \ \& \ cenY \leq (0.45 * h)$ then display ('Motor Cortex') and $cen_lobe=2$, and print Motor.txt.
- Next condition is $cenY > (0.45 * h) \ \& \ cenY \leq (0.55 * h)$ then display 'Sensory Cortex', and $cen_lobe=3$ and print Sensory.txt.
- Next condition start that is $cenY > (0.55 * h) \ \& \ cenY \leq (0.85 * h)$ then display 'Parietal Lobe & Temporal Lobe', and $cen_lobe=4$, and print Parietal.txt and Temporal.txt.
- Now it checks $cenY > (0.85 * h) \ \& \ cenY \leq h$ then display 'Occipital Lobe' and $cen_lobe=5$ and print Occipital.txt.
- Then $cen_lobe_prev = cen_lobe$ and
- Stop.

4.5 TUMOR SEGMENTATION & AREA COMPUTATION ALGORITHM

- Start
- Take binary MRI image in bw , define structure element $SE = strel('disk',0)$, $bw1 = imerode(bw,SE)$ then display image $bw1$ with title 'Eroded Binarised MRI Image Disk Radius:0'.
- Define structure element $SE = strel('disk',0)$, $bw1 = imdilate(bw1,SE)$ then display image bw with title 'Dilated Binarised MRI Image Disk Radius:0'.
- Define structural element $SE2 = strel('disk',1)$, $bw2 = imerode(bw1,SE2)$, then display image $bw2$ with titled 'Eroded Binarised MRI Image Disk Radius:1'.
- Define structural element $SE2 = strel('disk',1)$, $bw2 = imdilate(bw2,SE2)$, then display image $bw2$ with titled 'Dilated Binarised MRI Image Disk Radius:1'.
- Define structural element $SE3 = strel('disk',6)$, $bw3 = imerode(bw2,SE3)$ then display image $bw3$ with title 'Eroded Binarised MRI Image Disk Radius:6'.
- Define structural element $SE3 = strel('disk',6)$, $bw3 = imdilate(bw3,SE3)$ then display image with title 'Dilated Binarised MRI Image Disk Radius:6'.
- Now, compute $rec_width = rightx - leftx$, $rec_height = downy - topy$ and $tumor_area = rec_width * rec_height$ then display tumor area.
- Now it checks $topy$ conditions and $downy$ conditions and initialize $brain_affected_area=1$ and check if $cen_lobe_prev \sim top_lobe$ then $brain_affected_area = brain_affected_area + 1$.
- Next condition checks if $cen_lobe_prev \sim bottom_lobe$ then $brain_affected_area = brain_affected_area + 1$ and display $brain_affected_area$ and open result.txt using $fid = fopen('Result.log','w')$
- Print $brain_affected_area$, $tumor_area$

- Close & save file using fclose(fid) then pause for 1 sec. and print result.log
- call main menu
- Stop.

5. Implementation & Results:

The main aspects of the research thesis here is to make sure that this study should be able to identify the major cause and trying to provide the solution to the cause. That is our major concern lies for the fact that study need to identify the image then the major work was to filter the noise then it needs to detect the Skull and the orientation, should be done side by side .Then the next work would be to detect the tumor and Localization ,after that tumor segmentation and area computation is to be done .As a result at the end Research will come to an end when it will be able to recognize the area or location of the tumor.

Choice no : 1 Input MRI Image

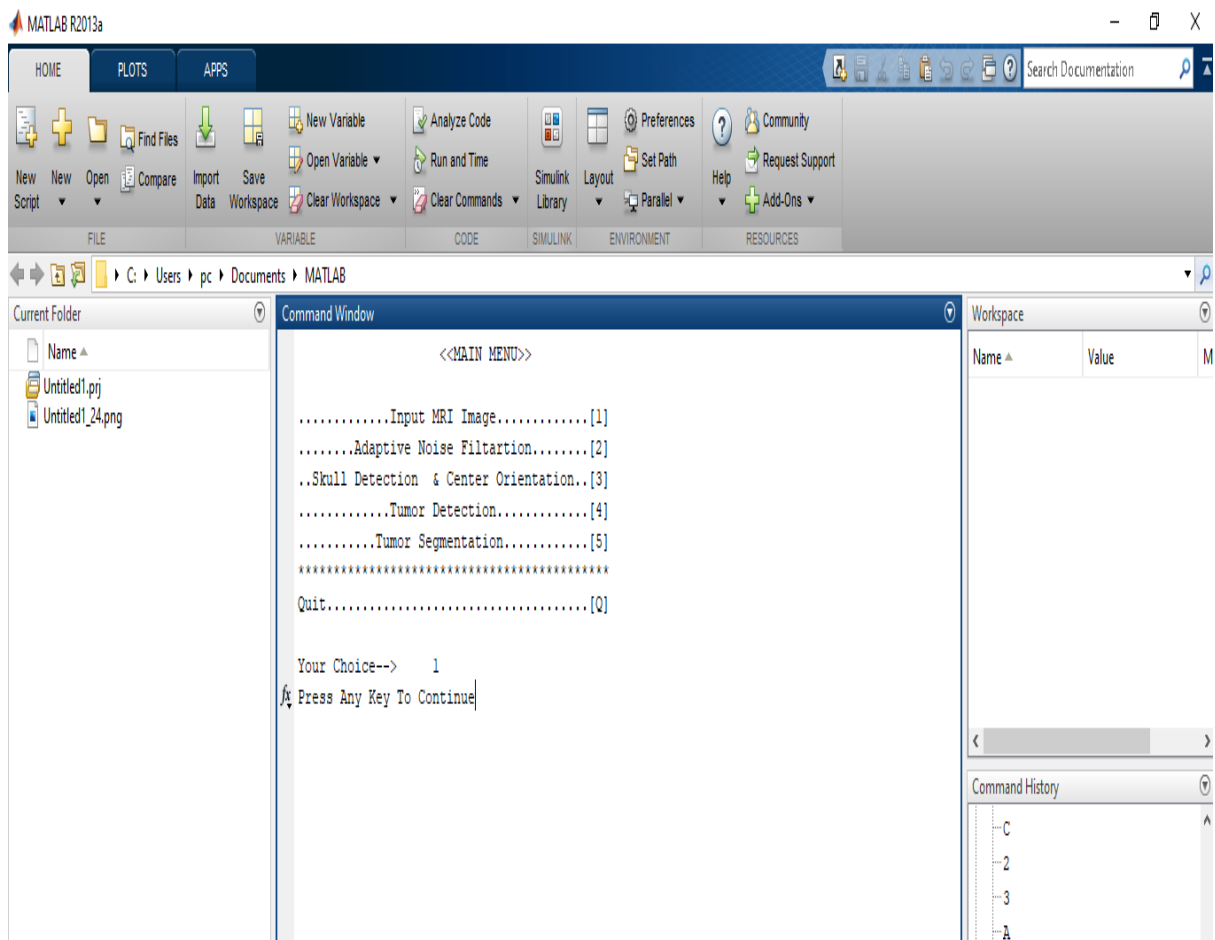


Fig 5.1 Choice 1 Input MRI Image

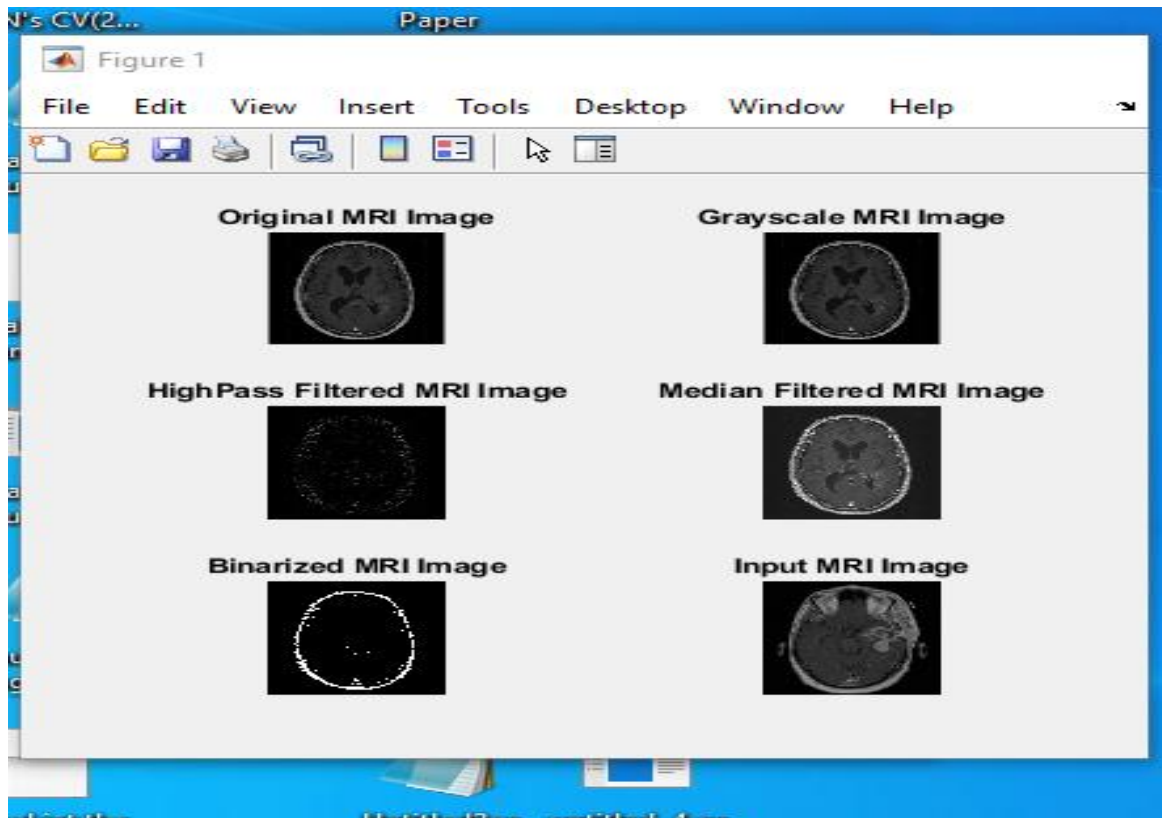


Fig 5.2 Input MRI Image

Choice no : 2 Adaptive Noise Filtration

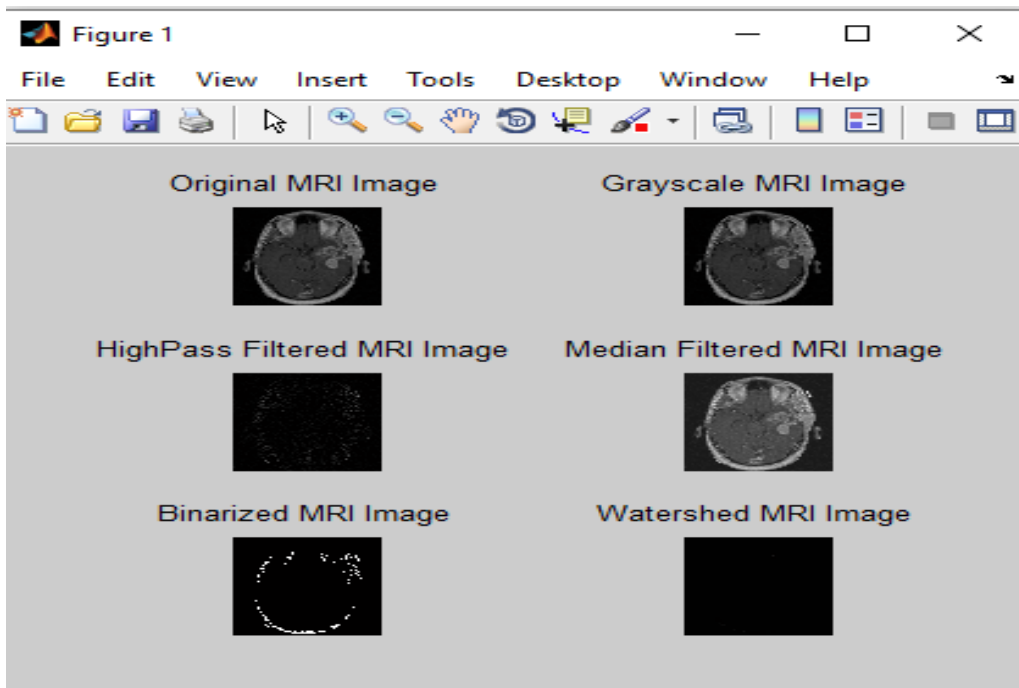


Fig 5.3 Adaptive Noise Filtration

Choice no : 3 Skull Detection & Centre Orientation

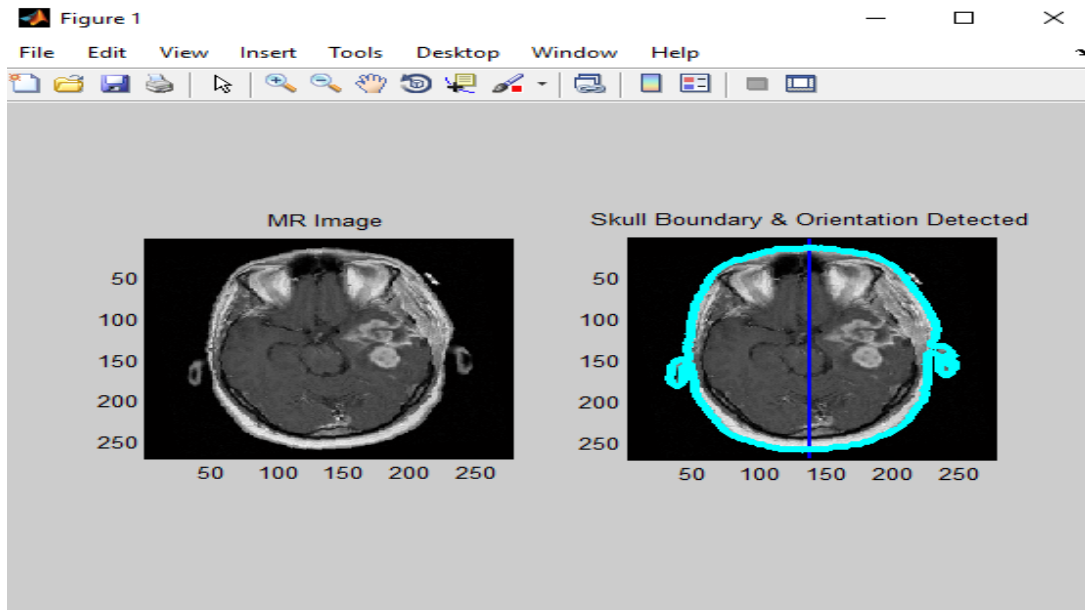


Fig 5.4 Skull Detection & Centre Orientation

Choice no : 4 Tumor Detection & Localization

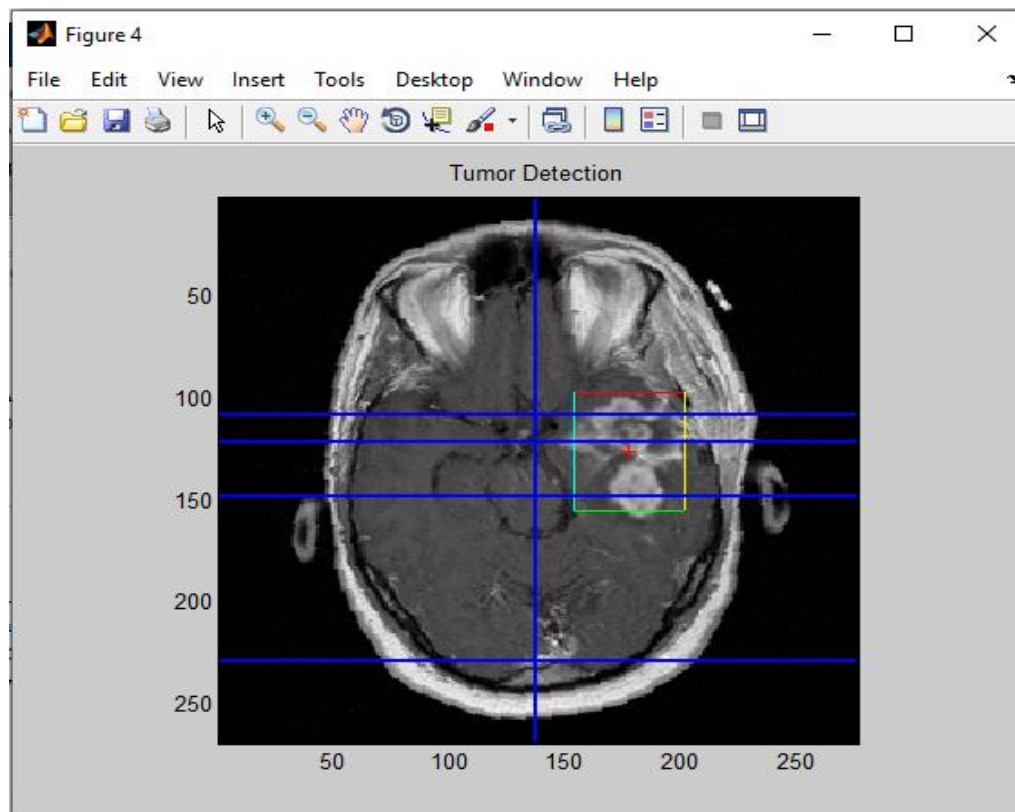


Fig 5.5 Tumor Detection

Description from Doctor

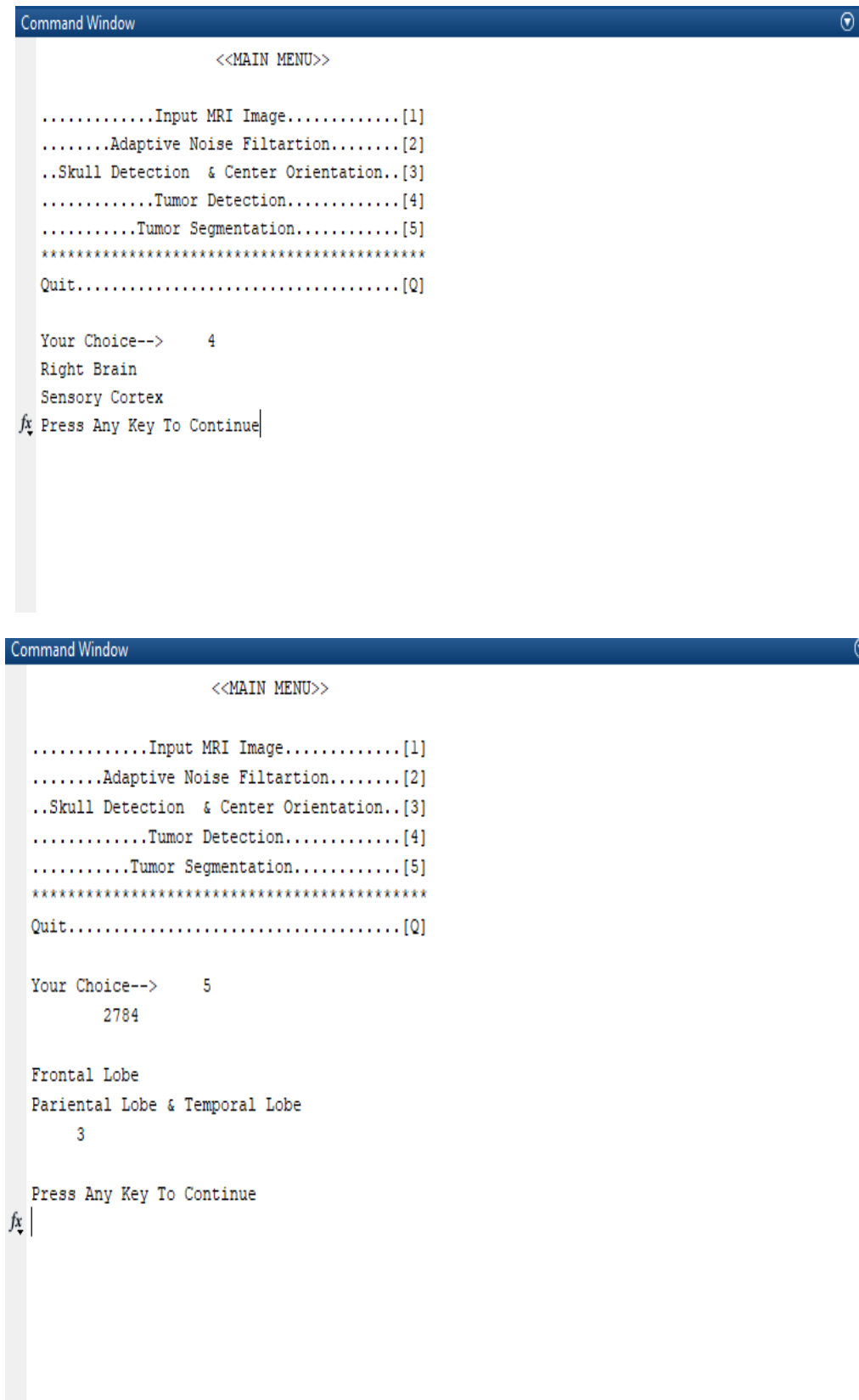


Fig 5.6 Description from Doctor

Graphical representation of Tumor Detection in Vertical Direction

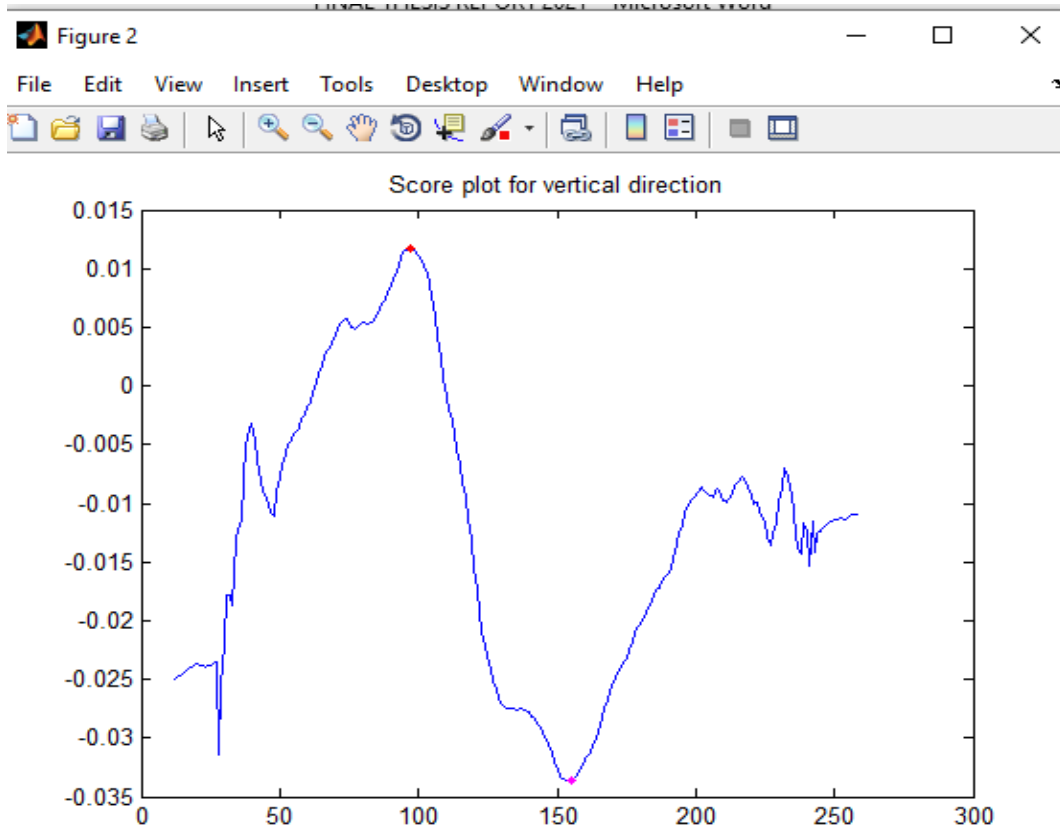


Fig 5.7 Tumor Detection in Vertical Direction

Graphical representation of Tumor Detection in Horizontal Direction

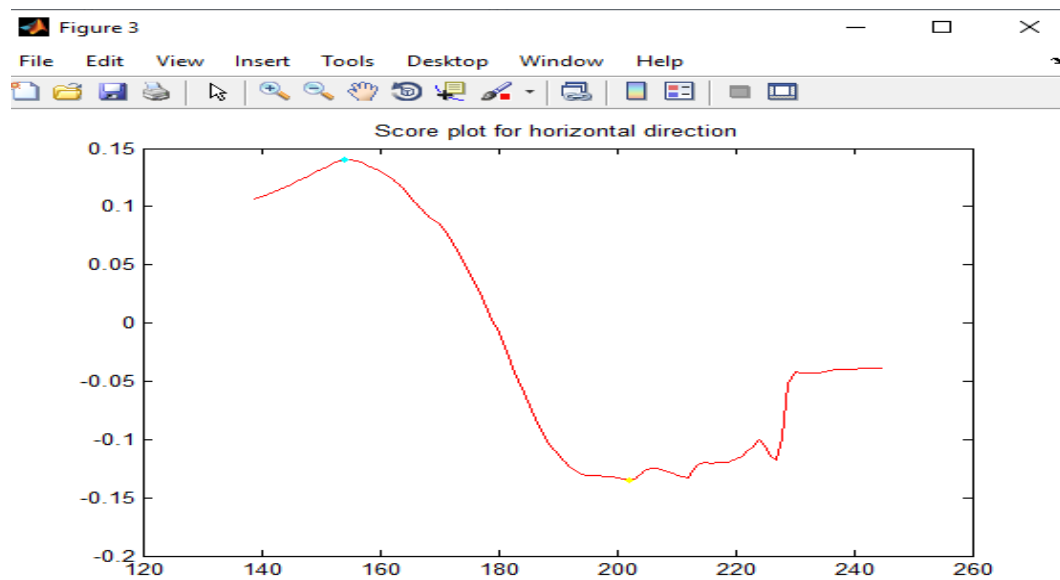


Fig 5.8 Tumor Detection in Horizontal Direction

Choice no : 5 Tumor Segmentation and Area Computation

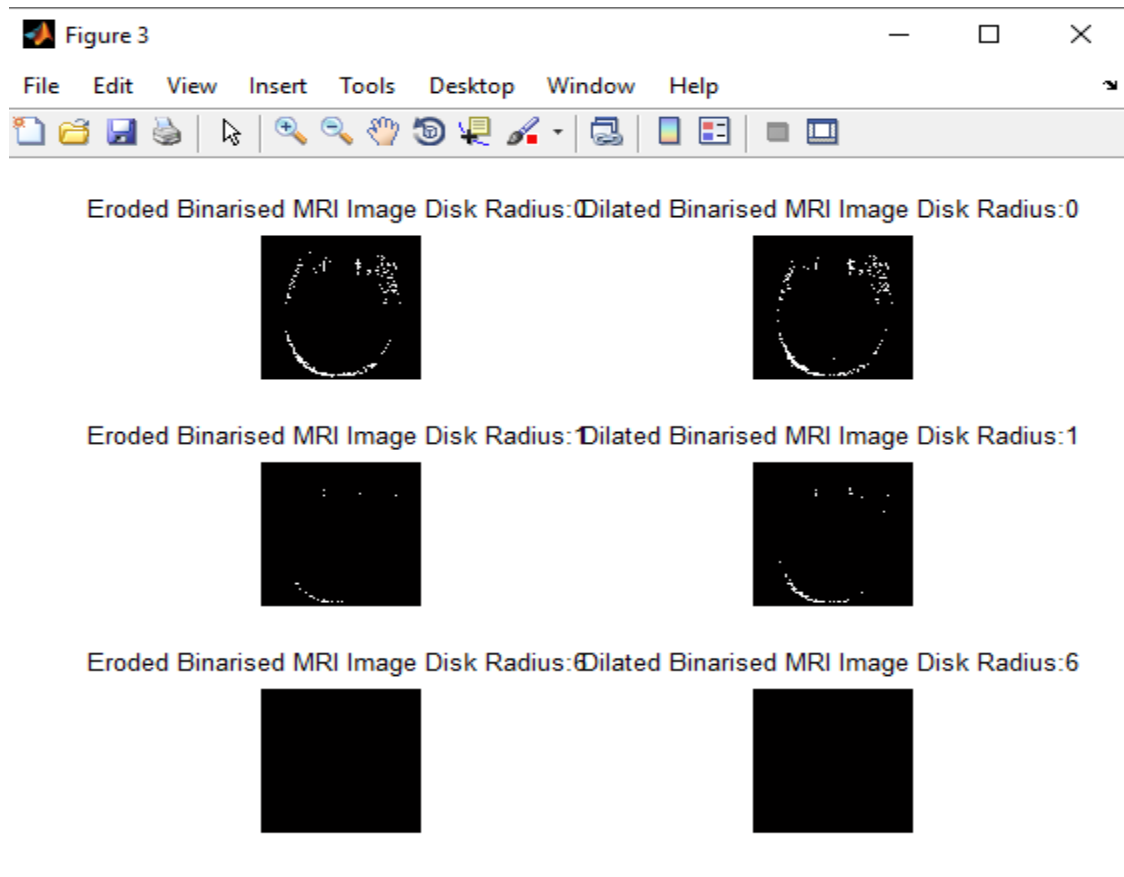
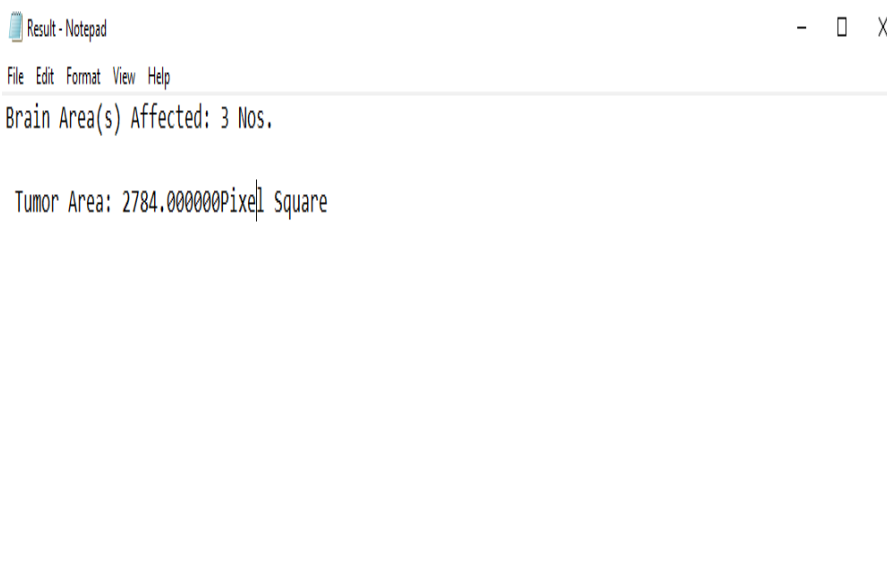


Fig 5.9 Tumor Segmentation

Area Computation



Conclusion:

The proposed exhaustive computerized crossover set of rules that implies for MRI picture handling for mind tumor identification and even the class. The proposed contraction could be utilized in order to define the basic fundamental necessities for tumor discovery like division, enlistment, Tumor identification and the class and even more and so forth. The proposed method has been completed in MATLAB by using MATLAB center capacity and photo handling tool stash. The proposed framework has been applied as a reasonable fall that could typifies every one of the significant advances and different methods that needs for definite tumor identification. Significant classification of steps have been taken that being GUI based completely input picture choice, versatile enough and commotion filtration skull recognition and focus direction, tumor discovery and division. The proposed framework not only handiest recognizes and sections a tumor yet mandatorily also processes significant boundaries which incorporate tumor length/region. Furthermore the proposed contraction can find the element of mind experiencing tumor and show related manifestations and anticipation connection. This proposed framework that joins numerous techniques that must be including the cerebrum area/limit that is divided for the division for skull recognition, Bhattacharya coefficient in even and vertical ways for tumor identification, rule based absolutely fluffy sound judgment for mind part influenced realities uncover and morphology for tumor division.

Reference:

1. Sukanta Kumar Tulo, Madhusmriti Nayak, Manish Kumar, Khushboo," *Brain Tumor Detection from MRI Image using Digital Image Processing*" International Journal of Engineering and Advanced Technology (IJEAT) ISSN: 2249-8958 (Online), Volume-6 Issue-4, April 2017
2. Md Shahariar Alam , Md Mahbubur Rahman 1., Mohammad Amazad Hossain , Md Khairul Islam , Kazi Mowdud Ahmed , Khandaker Takdir Ahmed , Bikash Chandra Singh and Md Sipon Miah " *Automatic Human Brain Tumor Detection in MRI Image Using Template-Based K Means and Improved Fuzzy C Means Clustering Algorithm*".*Big Data Cogn. Comput.* 2019, 3(2), 27
3. Md Shahariar Alam , Md Mahbubur Rahman 1., Mohammad Amazad Hossain , Md Khairul Islam , Kazi Mowdud Ahmed , Khandaker Takdir Ahmed , Bikash Chandra Singh and Md Sipon Miah ," *Automatic Human Brain Tumor Detection in MRI Image Using Template-Based K Means and Improved Fuzzy C Means Clustering Algorithm*".*Big Data Cogn. Comput.* 2019, 3(2), 27
4. Lay-Khoon Lee, Siau-Chuin Liew, AUGUST 2015," *A Survey of Medical Image Processing Tools*", [10.13140/RG.2.1.3364.4241](https://doi.org/10.13140/RG.2.1.3364.4241)
5. Xiangbin Liu , Liping Song , Shuai Liu and Yudong Zhang , January 2021" *A Review of Deep-Learning-Based Medical Image Segmentation Methods*", [Research on Sustainability and Artificial Intelligence](#)
6. P. Nagabushanam, S. Satheesh Kumar, J. Sunitha Kumar, S. Thomas George," *Brain Mri Image Segmentation using Improved Sobel Method*"International Journal of Recent

Technology and Engineering (IJRTE) ISSN: 2277-3878 (Online), Volume-7 Issue-4, September 2018.

7. R. Kavitha, Dr. C. Chellamuthu, Ms. KavinRupa “An Efficient Approach for Brain Tumour Detection Based on Modified Region Growing and Neural Network in MRI Images” International Conference on Computing, Electronics and Electrical Technologies [ICCEET] IEEE Xplorer 2011, pp(1087 – 1096).
8. Aamir Ahmad “Pathways to Breast Cancer Recurrence” Hindawi Publishing Corporation ISRN Oncology Volume 2013, Article ID 290568, 16 page <http://dx.doi.org/10.1155/2013/290568>, pp(1-17).
9. Ahmed KHARRAT Mohamed Ben MESSAOUD Nacéra BENAMRANE Mohamed ABID “Detection of Brain Tumor in Medical Images”, International Conference on Signals, Circuits and Systems 2009 IEEE, pp(1-6).
10. Bryan Cunitz, Barbrina Dunmire, Marla Paun, Oleg Kaundinya Gopinath “Brain Functional Localization: Survey of Image Registration Techniques”, IEEE TRANSACTIONS ON MEDICAL IMAGING, VOL. 26, NO. APRIL 2007 pp(427-450).
11. Selkar, R.G.; Thakare, M. Brain tumor detection and segmentation by using thresholding and watershed algorithm. *Int. J. Adv. Inf. Commun. Technol.* 2014, 1, 321–324.
12. Borole, V.Y.; Nimbhore, S.S.; Kawthekar, D.S.S. Image Processing Techniques for Brain Tumor Detection: A Review. *Int. J. Emerg. Trends Technol. Comput. Sci.* 2015, 4, 28–32.
13. Mustaqeem, A.; Javed, A.; Fatima, T. An efficient brain tumor detection algorithm using watershed & thresholding based segmentation. *Int. J. Image Graph. Signal Process.* 2012, 4, 34–39.
14. Kaur, H.; Mittal, M. Region Based Image Segmentation for Brain Tumor Detection. *Int. J. Eng. Manag. Res.* 2016, 6, 31–34.
15. Sinha, K.; Sinha, G. Efficient segmentation methods for tumor detection in MRI images. In *Proceedings of the IEEE 2014 IEEE Students’ Conference on Electrical, Electronics and Computer Science, Bhopal, India, 1–2 March 2014*; pp. 1–6.
16. Singh, A.; Parveen. Detection of brain tumor in MRI images, using combination of fuzzy c-means and SVM. In *Proceedings of the 2015 2nd International Conference on Signal Processing and Integrated Networks (SPIN), Noida, India, 19–20 February 2015*; pp. 98–102.
17. Dhanalakshmi, P.; Kanimozhi, T. Automatic segmentation of brain tumor using K-Means clustering and its area calculation. *Int. J. Adv. Electr. Electron. Eng.* 2013, 2, 130–134.